



Coding stage:

Hepatobiliary and Pancreatic cancer

Liesbet Van Eycken

Hepatobiliary and Pancreatic Cancer and TNM...

Separate classifications for:

- **Liver** => Hepatocellular carcinoma
- **Intrahepatic Bile Ducts**
 - Intrahepatic cholangiocarcinoma, cholangiocellular carcinoma, and combined hepatocellular and cholangiocarcinoma (mixed)
- **Gallbladder and Cystic Duct:** carcinomas
- **Perihilar Bile Ducts** (Klatskin tumour): Right, Left & Common Hepatic Ducts: carcinoma
- **Distal Extrahepatic Bile Duct** (distal to the insertion of the cystic duct): carcinoma
- **Ampulla of Vater:** carcinoma
- **Pancreas:** exocrine pancreas and/or high grade NE carcinomas (well diff=> see NET)

General rules

T-category: always TX – T0 – Tis

mostly: dimensions, invasion (vessels, adjacent organs)

M-category: always M0 or M1

cT categories correspond to pT categories

cN categories correspond to pN categories

N: specific lymph node regions

Contents

IICC, TNM 8th edition, 2016

Preface	XII
Acknowledgments	XIV
Organizations Associated with the TNM System	XV
Members of UICC Committees Associated with the TNM System	XVI
Section Editors	XVII

Introduction

Head and Neck Tumours	17
Lip and Oral Cavity	18
Pharynx	22
Larynx	31
Nasal Cavity and Paranasal Sinuses	36
Unknown Primary – Cervical Nodes	40
Malignant Melanoma of Upper Aerodigestive Tract	45
Major Salivary Glands	47
Thyroid Gland	51

Digestive System Tumours	55
Oesophagus and Oesophagogastric Junction	57
Stomach	63
Small Intestine	67
Appendix	70
Colon and Rectum	73
Anal Canal and Perianal Skin	77
Liver	80
Intrahepatic Bile Ducts	83
Gallbladder	85
Perihilar Bile Ducts	87
Distal Extrahepatic Bile Duct	89
Ampulla of Vater	91

Pancreas	93
Well-Differentiated Neuroendocrine Tumours of the Gastrointestinal Tract	96

Lung, Pleural, and Thymic Tumours	105
Lung	106
Pleural Mesothelioma	113
Thymic Tumours	115

Tumours of Bone and Soft Tissues	119
Bone	120
Soft Tissues	124
Gastrointestinal Stromal Tumour (GIST)	127

Skin Tumours	131
Carcinoma of Skin	133
Skin Carcinoma of the Head and Neck	136
Carcinoma of Skin of the Eyelid	139
Malignant Melanoma of Skin	142
Merkel Cell Carcinoma of Skin	147

Breast Tumours

Gynaecological Tumours	159
Vulva	161
Vagina	164
Cervix Uteri	166
Uterus – Endometrium	171
Uterine Sarcomas	175
Ovarian, Fallopian Tube, and Primary Peritoneal Carcinoma	179
Gestational Trophoblastic Neoplasms	184

Urological Tumours

Penis	188
Prostate	191
Testis	195
Vagina	199

Renal Pelvis and Ureter	202
Urinary Bladder	204
Urethra	208

Adrenal Cortex

Ophthalmic Tumours	215
Carcinoma of Conjunctiva	216
Malignant Melanoma of Conjunctiva	218
Malignant Melanoma of Uvea	221
Retinoblastoma	226
Sarcoma of Orbit	230
Carcinoma of Lacrimal Gland	232

Hodgkin Lymphoma

Non-Hodgkin Lymphomas

Essential TNM

Paediatric Tumours	247
Gastrointestinal Tumours	247
Bone and Soft Tissue Tumours	248
Gynaecological Tumours	249
Urological Tumours	250
Ophthalmic Tumours	251
Malignant Lymphoma	252
Central Nervous System	252

Liver: T, N and M-category (C22.0)

T-category based on

- Presence of vascular invasion: radiologically or pathologically assessed
- Number of tumour nodules (single <> multiple)
- Size of the largest tumour
 - T1a Solitary tumour 2 cm or less in greatest dimension with or without vascular* invasion
 - T1b Solitary tumour more than 2 cm in greatest dimension without vascular invasion
 - T2 Solitary tumour with vascular invasion more than 2 cm dimension *or* multiple tumours, none more than 5 cm in greatest dimension
 - T3 Multiple tumours any more than 5 cm in greatest dimension
 - T4 Tumour(s) involving a major branch of the portal or hepatic vein with direct invasion of adjacent organs (including the diaphragm), other than the gallbladder *or* with perforation of visceral peritoneum

N-category: N0-N1

M-category: M0-M1

The regional lymph nodes are the hilar, hepatic (along the proper hepatic artery), periportal (along the portal vein), inferior phrenic, and caval nodes.

Intrahepatic bile ducts (C22.1): T, N and M-category

T-category based on

- Presence of vascular invasion: radiologically or pathologically assessed
- Number of tumour nodules (single <> multiple)
- Size of the largest tumour
- Presence of visceral peritoneal perforation +/- direct involvement of local extrahepatic structures
 - T1a Solitary tumour 5 cm or less in greatest dimension without vascular invasion
 - T1b Solitary tumour more than 5 cm in greatest dimension without vascular invasion
 - T2 Solitary tumour with intrahepatic vascular invasion *or* multiple tumours, with or without vascular invasion
 - T3 Tumour perforating the visceral peritoneum
 - T4 Tumour involving local extrahepatic structures by direct hepatic invasion

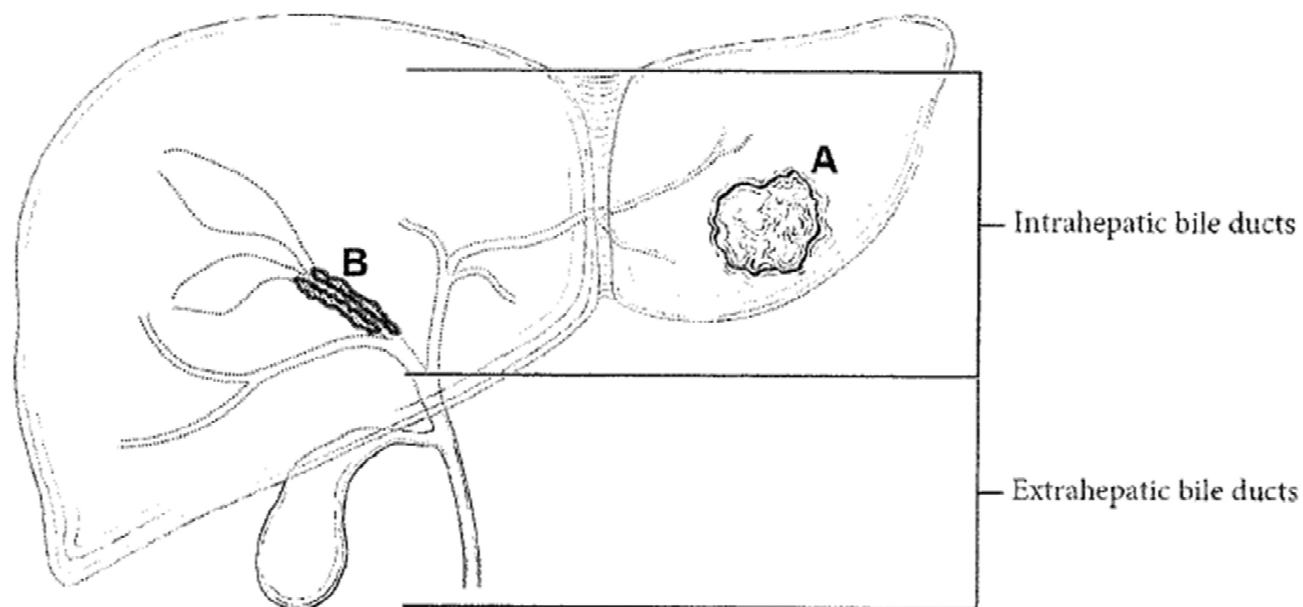
Note: invasion in gallbladder = T3

N-category: N0-N1

M-category: M0-M1 (also spread to the coeliac and/or periaortic and caval lymph nodes=M1)

Intrahepatic vs extrahepatic bile ducts

Liver diagram: intrahepatic bile ducts versus extrahepatic bile ducts



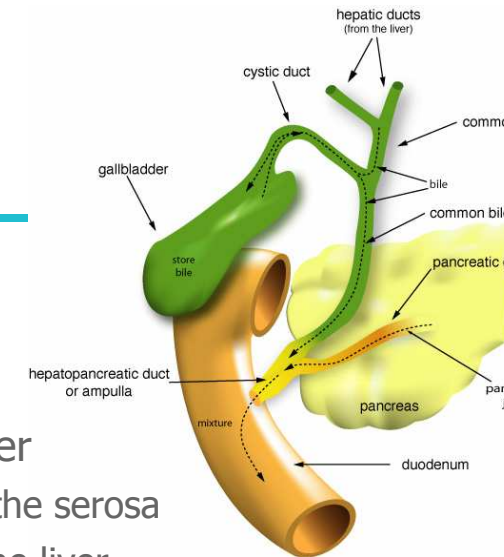
Gallbladder (and cystic duct) c23.0 – c24.0

- T1 Tumour invades lamina propria or muscular layer
 - T1a Tumour invades lamina propria
 - T1b Tumour invades muscular layer
- T2 Tumour invades perimuscular connective tissue; no extension beyond serosa or into liver
 - T2a Tumour invades perimuscular connective tissue on the peritoneal side with no extension to the serosa
 - T2b Tumour invades perimuscular connective tissue on the hepatic side with no extension into the liver
- T3 **Tumour perforates the serosa** (visceral peritoneum) and/or **directly invades** the liver and/or **one** other adjacent organ/structure, such as stomach, duodenum, colon, pancreas, omentum, extrahepatic bile ducts
- T4 Tumour invades main **portal vein or hepatic artery** or invades ≥ 2 extrahepatic organs or structures

Regional Lymph Nodes

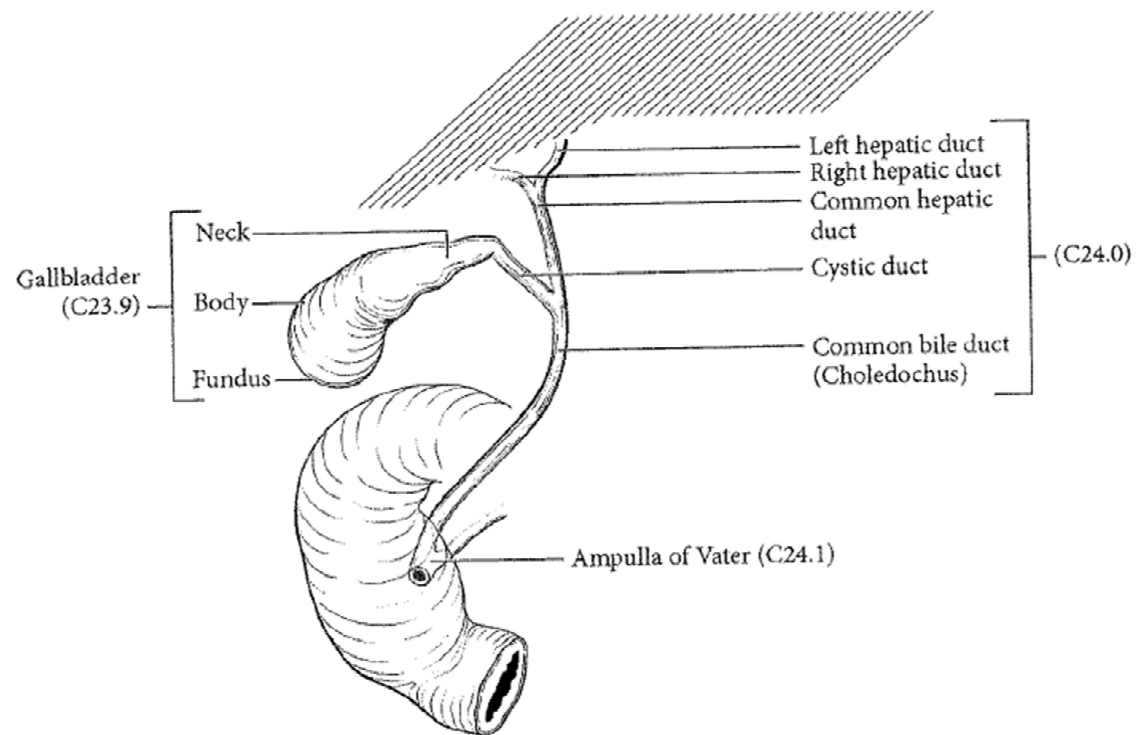
Regional lymph nodes are the hepatic hilus nodes (including nodes along the common bile duct, hepatic artery, portal vein, and cystic duct), coeliac, and superior mesenteric artery nodes.

N0 - N1= 1-3 nodes, N2 = 4 or more nodes



Perihilar bile ducts

Gallbladder in relation to the liver and biliary tract



Perihilar bile ducts

Proximal or perihilar bile ducts only

- T1 Tumour confined to the bile duct, with extension up to the muscle layer or fibrous tissue
- T2a Tumour invades beyond the wall of the bile duct to surrounding adipose tissue
- T2b Tumour invades adjacent hepatic parenchyma
- T3 Tumour invades unilateral branches of the portal vein or hepatic artery
- T4 Tumour invades the main portal vein or its branches bilaterally; or the common hepatic artery; or unilateral second-order biliary radicals with contralateral portal vein or hepatic artery involvement

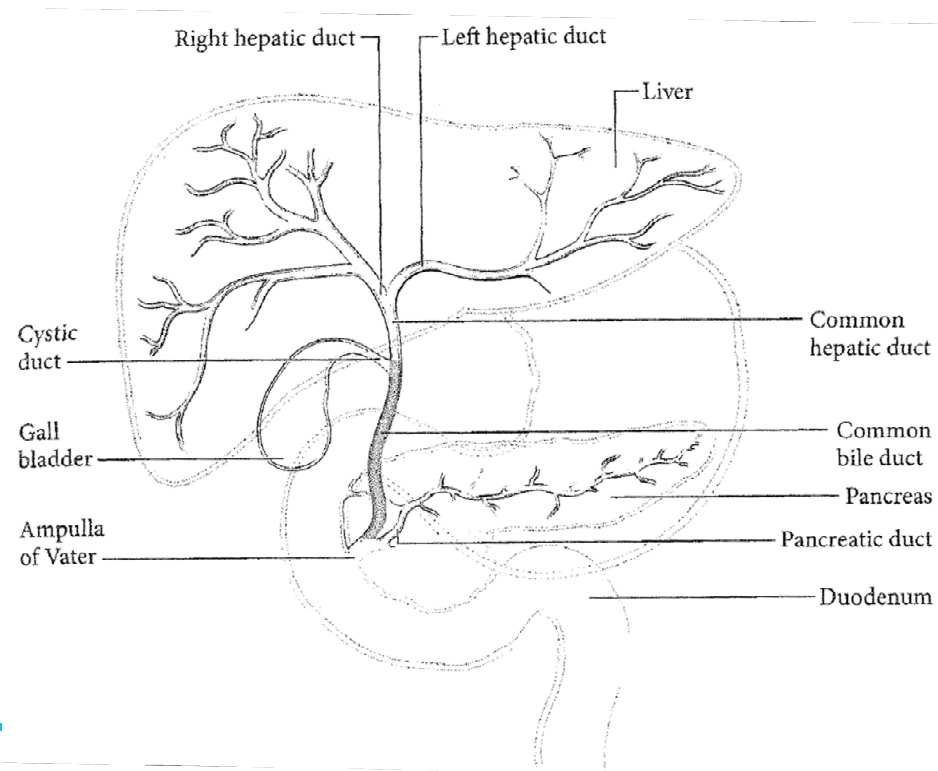
Regional Lymph Nodes

The regional nodes are the hilar and pericholedochal nodes in the hepatoduodenal ligament.

N0 - N1= 1-3 nodes, N2 = 4 or more nodes

Distal extrahepatic bile duct

distal bile ducts tumours. located between the confluence of the cystic duct and common hepatic duct and the ampulla of Vater (highlighted) (Modified from the College of American Pathologists).



Distal extrahepatic bile duct (C24.0)

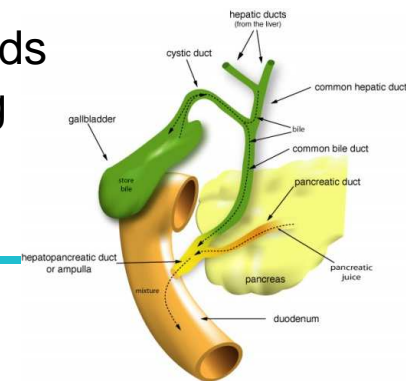
T-category: depth of invasion and invasion vessels

- T1 Tumour invades bile duct wall to a depth less than 5 mm
- T2 Tumour invades bile duct wall to a depth of 5 mm up to 12 mm
- T3 Tumour invades bile duct wall to a depth of more than 12 mm
- T4 Tumour involves the coeliac axis, the superior mesenteric artery and/ or the common hepatic artery

N-category

The regional lymph nodes are along the common bile duct, hepatic artery, back towards the coeliac trunk, posterior and anterior pancreaticoduodenal nodes, and nodes along the superior mesenteric artery

N0 - N1= 1-3 nodes, N2 = 4 or more nodes



Ampulla of Vater C24.1

T-category

- T1a Tumour limited to ampulla of Vater or sphincter of Oddi
- T1b Tumour invades beyond the sphincter of Oddi (peri-sphincteric invasion) and/or into the duodenal submucosa
- T2 Tumour invades the muscularis propria of the duodenum
- T3 Tumour invades pancreas
 - T3a Tumour invades 0.5 cm or less into the pancreas *or peripancreatic tissue*
 - T3b Tumour invades more than 0.5 cm into the pancreas or extends into peripancreatic tissue or duodenal serosa but without involvement of the celiac axis or the superior mesenteric artery
- T4 Tumour with **vascular involvement** of superior mesenteric artery or celiac axis or common hepatic artery

The regional lymph nodes are the same as for the head of the pancreas and are the lymph nodes along the common bile duct, common hepatic artery, portal vein, pyloric, infrapyloric, subpyloric, proximal mesenteric, coeliac, posterior and anterior pancreaticoduodenal vessels, and along the superior mesenteric vein and right lateral wall of the superior mesenteric artery.

N0 - N1= 1-3 nodes, N2 = 4 or more nodes

Pancreas (C25): T-category

- Exocrine pancreas and/or high grade NE carcinomas, Well diff NET of the pancreas => see NET

T-category: dimension and invasion artery

- T1 Tumour **2 cm or less** in greatest dimension
 - T1a Tumour 0.5 cm or less in greatest dimension
 - T1b Tumour greater than 0.5 cm and *no more* than 1 cm in
 - T1c Tumour greater than 1 cm but no more than 2 cm in greatest dimension
- T2 Tumour **more than 2 cm but no more than 4 cm** in greatest dimension
- T3 Tumour **more than 4 cm** in greatest dimension
- T4 Tumour **involves** coeliac axis, superior mesenteric artery and/or common hepatic artery

Note: in the absence of arterial involvement, the T category is based on size regardless of invasion of adjacent organs or veins! Extrapancreatic extension: difficult to determine because the pancreas does not have a capsule.

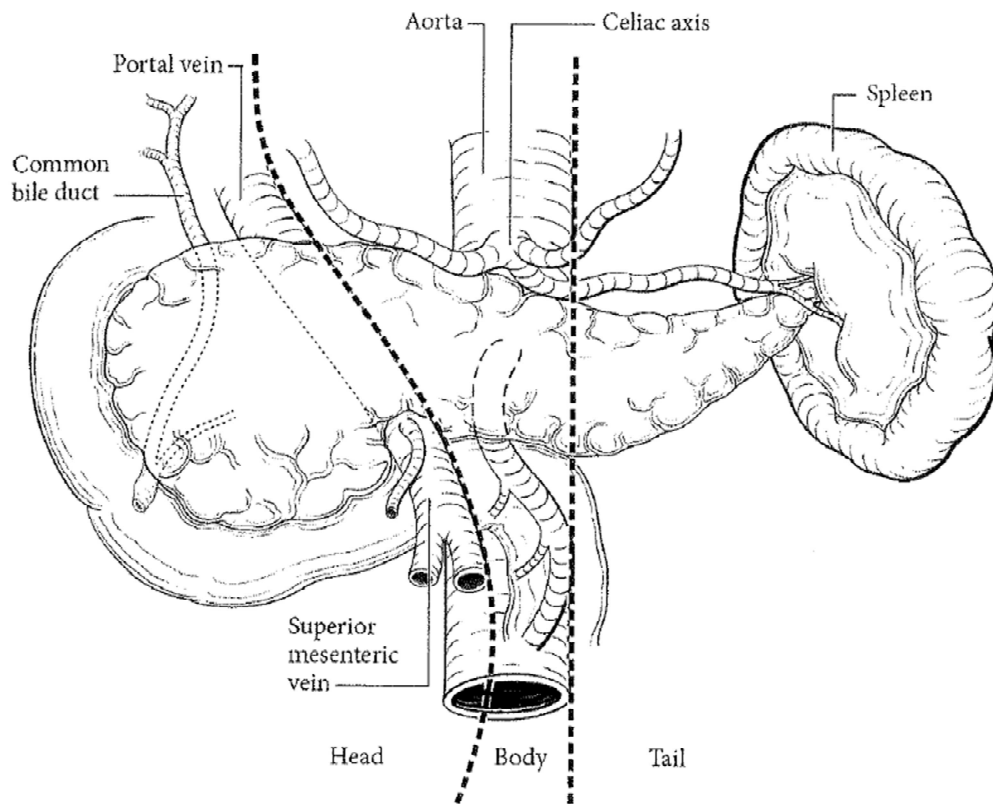
T4 => radiographic and endoscopic data cT4 (pT4)

Pancreas N-category

Regional Lymph Nodes

- The regional lymph nodes for **tumours in the head and neck** of the pancreas are the lymph nodes along the common bile duct, common hepatic artery, portal vein, pyloric, infrapyloric, subpyloric, proximal mesenteric, coeliac, posterior, and anterior pancreaticoduodenal vessels, and along the superior mesenteric vein and right lateral wall of the superior mesenteric artery.
- The regional lymph nodes for **tumours in body and tail** are the lymph nodes along the common hepatic artery, coeliac axis, splenic artery, and splenic hilum, as well as retroperitoneal nodes and lateral aortic nodes

Tumours of the pancreas



- Tumours of the **head of the pancreas** are those arising to the right of the superior mesenteric-portal vein confluence.
- Tumours of the **body of the pancreas** are those arising between the left border of the superior mesenteric vein and the left border of the aorta.
- Tumours of the **tail of the pancreas** are those arising between the left border of the aorta and the hilum of the spleen.

-
- Exercises hepatobiliary tract and pancreas
 - <https://create.kahoot.it/details/hepatobiliar-pancreas-exercises/bb36968a-962c-44e1-8cf6-300287b929f6>