

Instructions: code topography, morphology, cTNM and pTNM (if applicable). Note the primary consecutive treatments.

CASE #1

CASE HISTORY

Female (64 years) came to her doctor after finding a hard mass in her left breast. No nipple discharge or nipple retraction.

PHYSICAL EXAMINATION

Breast: 4 cm hard mass, lower outer quadrant of the left breast. On examination the skin was dimpled with **signs of oedema and peau d'orange**. Axilla left: palpable suspicious **nodes in the lower axilla**. No hepatomegaly or enlarged lymph nodes other than in left axilla.

DIAGNOSTIC PROCEDURES

18/06/20XX Mammography: suspect lesion in *lower outer quadrant of the left breast*
18/06/20XX Chest X-ray: normal
21/06/20XX Needle biopsy, left breast

PATHOLOGY

21/06/20XX Needle biopsy: poorly differentiated infiltrating duct carcinoma. Oestrogen and progesterone receptors positive.

SURGERY

06/07/20XX Modified radical mastectomy

OPERATIVE REPORT

06/07/20XX Skin tightly adherent to **3.5 cm** gritty mass, left **upper inner quadrant** in fatty breast tissue just below dermis. Dissection of axilla.

PATHOLOGY

06/07/20XX Modified radical mastectomy: poorly differentiated infiltrating ductal carcinoma with infiltration of dermis, but no ulceration of the skin surface, largest diameter 3 cm. Second lesion of 0.8 cm in diameter in lower inner quadrant, infiltrating lobular carcinoma. No areas of ductal carcinoma *in situ*. 6 out of 17 axillary lymph nodes involved (ductal carcinoma).

FURTHER TREATMENTS

Post-operative radiation therapy to axilla. Referred for adjuvant chemotherapy and hormonal treatment.

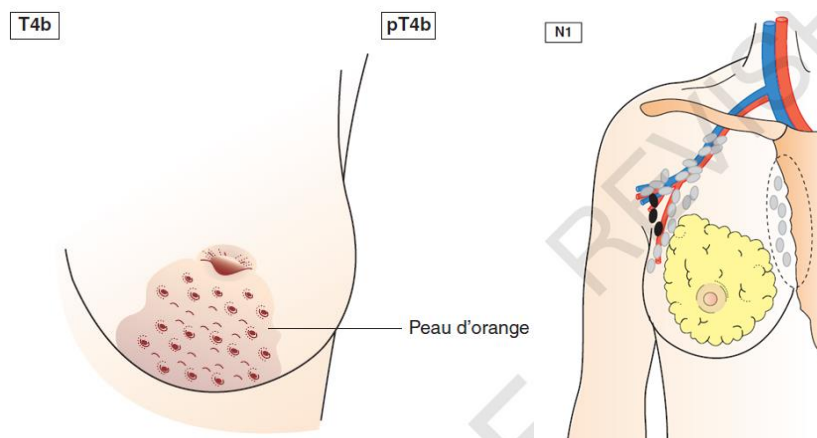
Remember how to start...

1. Determine primary site and histology
2. Look up site chapter
3. Is histology included in this chapter?
4. Review list of regional lymph nodes
5. Clinical versus pathologic stage
6. Find staging information in the tables
7. Determine T, N, M
8. (Assign stage on the basis of the T, N and M)

1. Topography upper inner quadrant of the left breast Code **C50.2 LEFT**
2. Morphology and grade Code **8522/3 grade 3**
3. Histology is included in the breast chapter
4. Clinical versus pathological stage

Clinical TNM cT **4b** _____ N **1** _____ M **0** _____

cT4b because of the skin oedema and peau d'orange

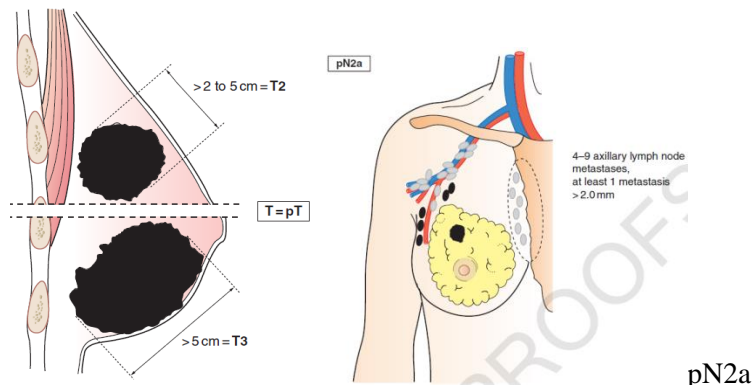


Pathological TNM pT **2(m)** _____ N**2a** _____ M _____

pT2(m) or: pT2(2)

m for multifocality, largest dimension taken into account to determine T2

Note: Invasion of the dermis alone does NOT qualify as T4!



CASE #2

CASE HISTORY

Male, 56 years. Patient lost 5 kg of weight during the last year. Chest pain, productive cough hoarseness with partial vocal cord paralysis. Smoker for over 30 years. Chest X-ray performed by GP shows as suspect lesion in the right lung.

PHYSICAL EXAMINATION

19/11/20XX Lungs, slight wheezing on expiration in both lungs. Tumour palpable supraclavicular right. Patient visibly lost weight, otherwise no abnormal findings.

DIAGNOSTIC PROCEDURES

19/11/20XX Laboratory tests: within normal limits

19/11/20XX CT-scan chest: 6 cm tumour mass in right upper lobe, incomplete atelectasis of the right lung. **Pleural effusion** apparent. Large mediastinal mass (both left and right).

20/11/20XX Supraclavicular biopsy

26/11/20XX Bronchoscopy with bronchial washing and biopsy: **right upper lobe mass noted with extension along lateral wall of main bronchus into the trachea.**

PATHOLOGY

20/11/20XX **Supraclavicular node biopsy: Metastatic squamous cell carcinoma.**

26/11/20XX Squamous cell carcinoma, poorly differentiated. Bronchial washings and brushings positive for malignant cells.

TREATMENT

Patient receives palliative radiotherapy

Topography upper lobe of the right lung _____ Code **C34.1 right** _____

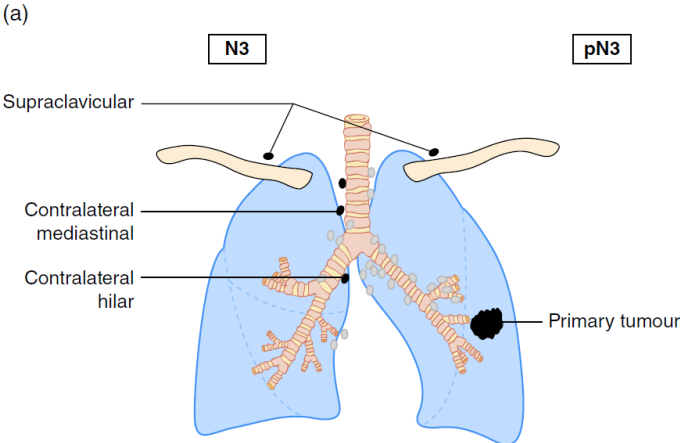
Morphology and grade squamous cell carcinoma _____ Code **8070/3 grade 3** _____

Clinical stage

Clinical TNM T4 _____ N 3 _____ M **1a** _____

cT4 mass noted with extension along lateral wall of main bronchus into the trachea

cN3 because of the supraclavicular node involvement



cM1a because of pleural effusion

CASE #3

CASE HISTORY

Female, 74 years. Passage of blood in stool of one-year duration , worse in last months. Progressive difficulty in evacuating bowels.

PHYSICAL EXAMINATION

Abdomen: Soft, non tender, and non distended with no evidence of masses. Digital rectal exam: no abnormalities.

DIAGNOSTIC PROCEDURES

25/08/20XX CT-scan chest and abdomen: no abnormalities.
27/08/20XX Colonoscopy: Fungating lesion involving more than 50% of the circumference of bowel at the splenic flexure of the colon. Biopsy.
27/08/20XX Liver enzymes: within normal limits .

PATHOLOGY

27/08/20XX Biopsy: adenocarcinoma

SURGERY

30/08/20XX Left hemicolectomy: lesion at the splenic flexure without evidence of gross lymphadenopathy. A suspicious lesion at the liver surface is biopsied.

PATHOLOGY

30/08/20XX Left hemicolectomy. Microscopy: Moderately differentiated mucinous adenocarcinoma showing **extension into the subserosa** and metastases in **6/10 mesocolic lymph nodes**. The visceral peritoneum is intact. Tumour size 5 cm. Liver biopsy: no evidence of tumour.

FUTHER TREATMENT

Patient receives adjuvant chemotherapy

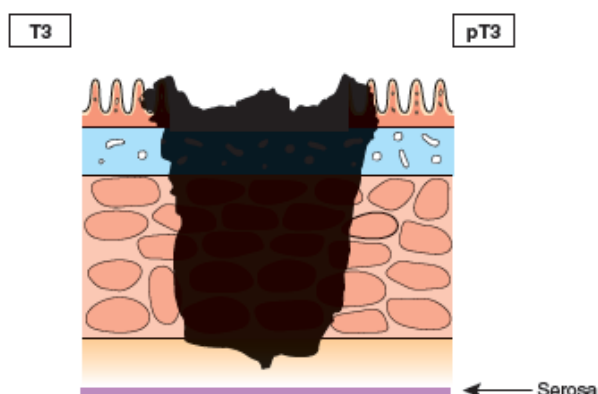
Topography **Splenic flexure of the colon** _____ Code **C18.5** _____

Morphology and grade **Mucinous adenocarcinoma** _____ Code **8480/3 grade 2** _____

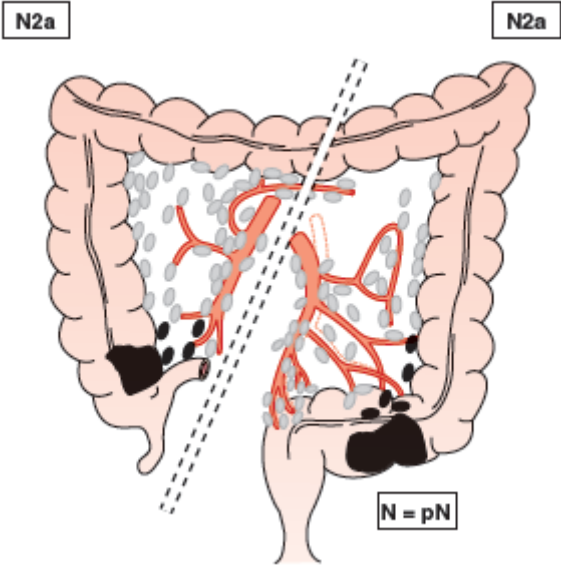
Clinical TNM Tx _____ N x _____ M **0** _____

Pathological TNM T **3** _____ N **2a** _____ M _____

pT3



pN2a



CASE #4

CASE HISTORY

Male, 76 years, in good condition, no comorbidity. Progressive difficulty urinating, especially starting and stopping while urinating. Decreased flow.

PHYSICAL EXAMINATION

Digital rectal examination: Enlargement of prostate bilaterally. Nodule in lower half of right lobe, protruding slightly more than right lobe and somewhat irregular.

DIAGNOSTIC PROCEDURES

- 19/03/20XX PSA: 43.4 (normal = 10)
- 22/03/20XX Chest X-ray: Normal; Pelvic CT scan: no of evidence of pelvic lymph node metastases
- 22/03/20XX Bone scan: Increased uptake in right ankle and right knee, felt to be due to arthritic changes. No clear signs of distant metastasis.
- 26/03/20XX Bilateral needle biopsies of the prostate.

PATHOLOGY

26/03/20XX Needle biopsies: left 3 out of 6 are positive, right 6 out of 6 are positive. Moderately differentiated adenocarcinoma. Gleason grade 3 + 4.

SURGERY

01/04/20XX Pelvic lymph node dissection. The urologist finds an enlarged suspicious lymph node and the pathologist is consulted intraoperatively for a frozen section procedure.

PATHOLOGY

01/04/20XX Frozen section procedure: one lymph node with metastatic adenocarcinoma, largest diameter 12 mm.

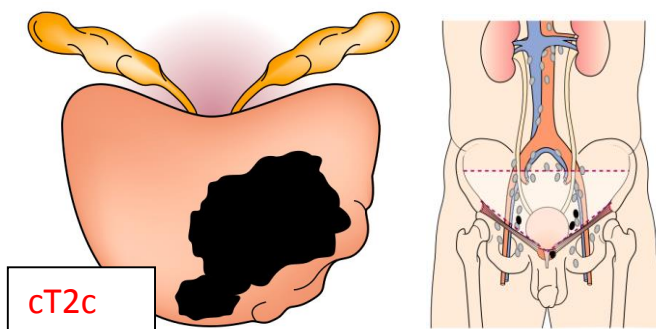
TREATMENT

Because of the discovery of the positive lymph node, the planned prostatectomy is abandoned and the patient receives radiotherapy and also starts with anti-androgen hormone therapy.

Topography **Prostate** _____ Code **C61.9** _____

Morphology and grade **adenocarcinoma** _____ Code **8140/3 grade 2 (Gleason grade 3+4)** _____

Clinical TNM **T 2c** _____ **N 1** _____ **M 0** _____



Pathological TNM **No surgery, no data available to make a p TNM: T ___ N ___ M ___**